

Contact Us

NNI@Changi General Hospital (CGH)
2 Simei Street 3, Singapore 529889
Email: appt_centre@cgh.com.sg

NNI@KK Women's and Children's Hospital (KKH)
100 Bukit Timah Road, Singapore 229899
Email: centralappt@kkh.com.sg

NNI@Khoo Teck Puat Hospital (KTPH)
90 Yishun Central, Singapore 768828
Email: ktph.appt@ktph.com.sg

NNI@Sengkang General Hospital (SKH)
110 Sengkang East Way, Singapore 544886
Email: appointments@skh.com.sg

NNI@Singapore General Hospital (SGH)
Outram Road, Singapore 169608
Email: appointments@sgh.com.sg

NNI@Tan Tock Seng Hospital (TTSH)
11 Jalan Tan Tock Seng, Singapore 308433
Email: appointments@nni.com.sg

NNI@Woodlands Health (WH)
17 Woodlands Drive 17, Singapore 737628
Email: appt@wh.com.sg

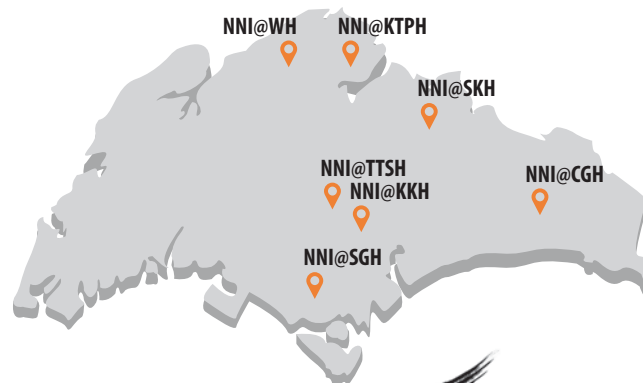Make an Appointment

Download **HealthHub** to make, change, or cancel your appointment online.

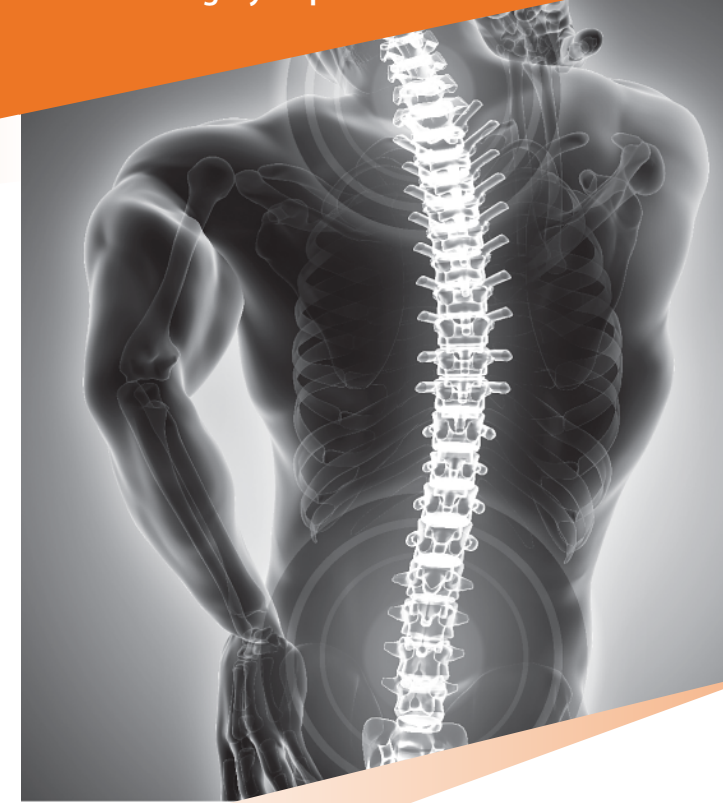

Scan the QR code to learn more about other neurological conditions

National Neuroscience Institute (NNI)
operates out of seven hospitals in Singapore:
CGH, KKH, KTPH, SKH, SGH, TTSH, WH



Neurosurgery Department



Spine and Spinal Disorders

Brochure content serves as a guide only
Speak to your doctor for more details

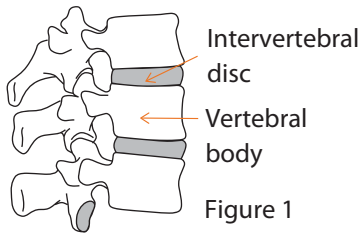
Updated March 2024



National
Neuroscience Institute
SingHealth

Understanding the Spine and Spinal Disorders

The spinal column spreads the body weight from the head to the pelvis and protects the spinal cord. It consists of bony vertebrae connected together by cartilage-like structures (discs) and ligaments (Figure 1).

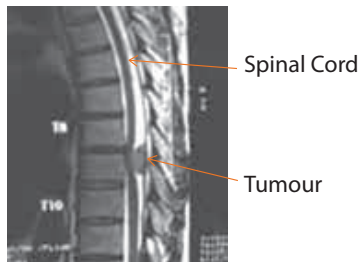


• Degenerative Disease of the Spine (Spondylosis)

The spine is subjected to wear and tear like all joints in the body, which changes the structure. Degeneration of the disc may cause it to bulge and compress the spinal cord or nerves.

• Tumours of the Spine

These may include tumours of the spinal column or the spinal cord (Figure 2). Tumours may be primary (originating from the spine) or secondary (spread from other sites like the lung or breast).



• Spinal Trauma

Injuries to the spine are common in road traffic and diving accidents and falls from height.

Signs of Spinal Disorders

Signs vary with each individual and type of spinal disorder. A person may experience:

- Neck and back stiffness or pain
- Pain running down arms and legs (Figure 3)
- Numbness or weakness of the arms and legs
- Muscle spasms
- Headache
- Unsteadiness

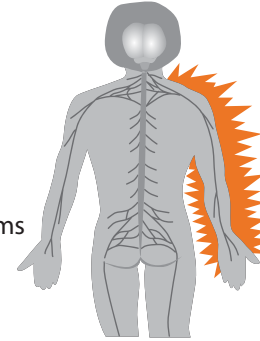


Figure 3
Pain running down arms

Diagnosing Spinal Disorders

These degenerative disorders are diagnosed through physical examination and confirmed by imaging studies including x-rays and Magnetic Resonance Imaging (MRI). The images may indicate abnormalities and reveal the extent of damage to the spine.

Treating Spinal Disorders

1. Degenerative Disease of the Spine (Spondylosis)

Treatment in most cases consists of conservative methods such as:

- **Medication**
 - The doctor may prescribe medication to relieve pain or muscle spasm.

• Physical Therapy and Activity Modification

- Hot/cold therapy, injections or an active exercise programme may help to relieve symptoms. Exercises can improve muscle strength and flexibility.
- Adopt good posture and avoid staying in the same position for prolonged periods of time.
- Practice proper lifting techniques and avoid bending at the waist level.

Intervention is required for more severe symptoms or failure to respond to therapy:

• Injection Therapy

- This involves injection which may help reduce pain.

• Surgical Treatment

- Surgery may be necessary if pain does not improve or when there are progressive neurological symptoms.

2. Tumours of the Spine

Treatment depends on the patient's condition, extent of tumour and severity of symptoms.

- Surgical decompression to relieve spinal cord or nerve pressure may be needed to obtain relief from symptoms. Additional procedures may be needed to stabilise the spine. Further treatment with radiotherapy and chemotherapy may also be necessary.

3. Spinal Trauma

- Surgery is needed in cases where the spine is unstable or when there is a bone fragment, blood clot or ruptured disc pressing on the spinal cord or nerve roots.